



Difficult Airway Evaluation

Evaluating for the difficult airway

Between 1 – 3% of patients who require endotracheal intubation have airways that make intubation difficult. Recognizing those patients who may have a difficult airway allows the paramedic to proceed with caution and to keep as many options open as possible. It also allows the paramedic to prepare additional equipment (such as a cricothyrotomy kit) that may not ordinarily be part of a standard airway kit. The mnemonic LEMON is useful in evaluating patients for signs that may be consistent with a difficult airway and should raise the paramedic's index of suspicion.

Look externally

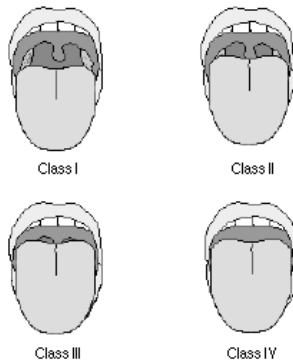
External indicators of either difficult intubation or difficult ventilation include: presence of a beard or moustache, abnormal facial shape, extreme cachexia, edentulous mouth, facial trauma, obesity, large front teeth or "buck teeth", high arching palate, receding mandible, short bull neck.

Evaluate 3-3-2 Rule

- 3 fingers between the patient's teeth (patient's mouth should open adequately to permit three fingers to be placed between the upper and lower teeth)
- 3 fingers between the tip of the jaw and the beginning of the neck (under the chin)
- 2 fingers between the thyroid notch and the floor of the mandible (top of the neck)

Mallampati

This scoring system is based on the work of Mallampati et al published in the Canadian Anaesthesia Society Journal in 1985. The system takes into account the anatomy of the mouth and the view of various anatomical structures when the patient opens his mouth as wide as possible. This test is performed with the patient in the sitting position, the head held in a neutral position, the mouth wide open, and the tongue protruding to the maximum. Inappropriate scoring may occur if the patient is in the supine position (instead of sitting), if the patient phonates or if the patient arches his or her tongue.



Class I (easy) = visualization of the soft palate, fauces, uvula, anterior and posterior pillars.

Class II = visualization of the soft palate, fauces and uvula.

Class III = visualization of the soft palate and the base of the uvula.

Class IV (difficult) = soft palate is not visible at all.

Obstruction?

Besides the obvious difficulty if the airway is obstructed with a foreign body, the paramedic should also consider other obstructers such as tumor, abscess, epiglottitis, or expanding hematoma.

Neck Mobility

Ask the patient to place their chin on their chest and to tilt their head backward as far as possible. Obviously, this will not be possible in the immobilized trauma patient.